

The mandibular complex*

Kalevi Koski

Turku, Finland

(*Transaction of the European Orthodontic Society 1974, pp. 53–67*)

*Die Wahrheit mag uns zu allem möglichen führen
Brecht: Leben des Galilei*

The mandible can be called the orthodontist's complex. A complex often defies reason and this is true of many orthodontists' views on this bone. Voluminous literature exists about the lower jaw but one issue, namely the mandibular amenability to our mechanotherapy, is still the subject of great debate, dividing the orthodontic world into two opposite camps, in spite of the fact that the evidence for the solution has been there for a long time in the numerous clinical observations and research findings.

The mandible is also complex from the biological viewpoint since it consists of several relatively independent structural and functional parts. As regards its adaptability, especially where intermaxillary relationships are concerned, the key region is perhaps the evolutionary newcomer, the ramus-condyle region. It is the purpose of this presentation to review some of the most recent findings related to the condyle and the ramus in the hope that every clarification of the complex mandible will reduce the mandibular complex of the orthodontists. Let us first consider the condylar cartilage. How does the condylar cartilage grow?

It is commonly accepted to-day that the condylar cartilage, unlike the so-called growth cartilages proper, grows appositionally, not interstitially and that the mitotic cells are not cartilage cells, as in the growth cartilages, but undifferentiated mesenchymal cells (Fig. 1).

These cells are apparently multipotential, as are similar cells elsewhere. Specifically, they can become either chondrogenic or osteogenic, depending on environmental stimuli (Meikle, 1973). This makes it understandable why condylar cartilage transplants behave as they do. It has been shown repeatedly (Koski and Mäkinen, 1963; Koski and Rönning, 1965; Rönning, 1966; Duterloo, 1967, Rönning and Koski, 1970; Meikle, 1973) that the transplanted post-natal condylar cartilage of a rat does not maintain its cartilaginous nature, but becomes ossified. Yet, while we may now understand this peculiar phenomenon better than before, we still have no clear, detailed explanation for it.

An interesting recent finding is that there seem to be two kinds of cells in the mitotic layer of the condylar cartilage (Bremers, 1973), and also among the chondrocytes (Silbermann and Frommer, 1973). The function of these cells is not known yet. However, a similar cellular

heterogeneity has been found in other cartilages, where the different cells are apparently involved in the production of different constituents of the matrix (Kincaid, 1971; Smith, 1972). It remains to be seen whether the condylar cartilage cells divide their functions in the same fashion, i.e., whether a similarity between the condylar cartilage and the other cartilages exists in this respect.

On the basis of the existing bulk of evidence (for literature reviews, see Meikle, 1973; Koski, 1975), it can be stated at this time that the growth of the condylar cartilage, in terms of proliferative activity, can be influenced through environmental stimuli of a mechanical nature, and the same applies to the growth of the bony condyle-ramus region. In regard to the condylar cartilage, this has been attributed to the undifferentiated nature of the proliferating cells (Charlier *et al.*, 1969, Petrovic and Stutzmann, 1972), whose origin seems to be traceable to the periosteum of the mandibular ramus (Petrovic and Stutzmann 1972; Meikle, 1973).

It is well known that periosteal growth can be mechanically influenced. The periosteal growth of the ramus-condyle region has been found to be correlated with condylar growth (Charlier *et al.*, 1969), which may not surprise us (*vide supra et infra*). However, a postulate that remodelling changes in the ramus depend on the direction of condylar growth (Björk and Skieller, 1972) seems unjustified.

The lateral pterygoid muscle already occupies a suspiciously close relationship to the developing condyle during the foetal period (Yuodelis, 1966). Its role in regard to the condylar cartilage has been described as a 'common link' for controlling factors over the cartilage (Charlier *et al.*, 1969; Petrovic and Stutzmann, 1972; Petrovic *et al.*, 1973). However, there may still be a link missing in the picture.

In recent studies the relationship between the epiphyseal growth cartilage and the periosteum has been elucidated (Hert, 1964; Crilly, 1972), with very interesting conclusions, which can be summarized as follows: the epiphyseal growth plates are not even mechanically independent determinants of long bone growth, but depend on the environment; in the first place the periosteal tension apparently regulates the activity of the epiphyseal growth plates. In the light of this new concept the missing link would be the periosteum-perichondrium of the condyle and the ramus (cf. Petrovic *et al.*, 1973). It can be readily observed that the periosteum of the ramus and of the condylar neck, to which the fibres of the lateral pterygoid muscle are attached, continues without interruption as the fibrous capping layer of the condylar

* The First Sheldon Friel Memorial Lecture.

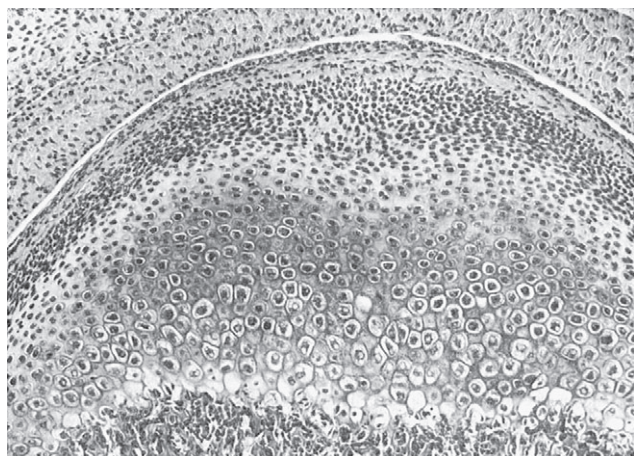


Figure 1 The top of the condyle of a 30-day-old rat. The mitotic cells form a dense band underneath the fibrous covering layer, then follow the chondrocytes, which soon become hypertrophic; in the lower edge of the view the erosion front. H & E, original magnification $\times 133$.

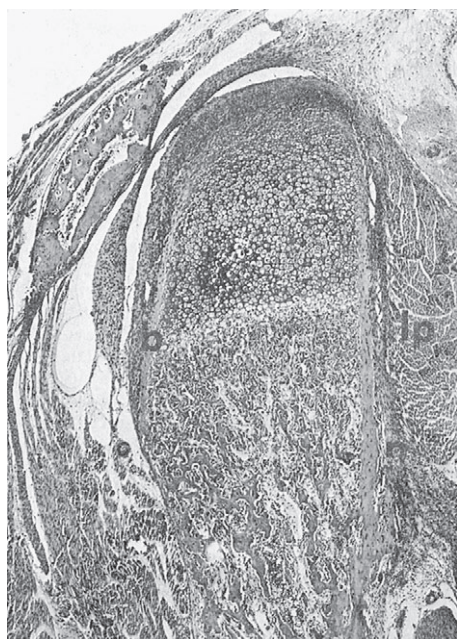


Figure 2 A frontal section of the condylar region of a 10-day-old rat. The periosteum (a) of the bone surfaces, to which the fibres of the lateral pterygoid muscle (lp) attach themselves, continues as the fibrous cover of the condylar cartilage. Note that the periosteal bone tube (b) continues up to the beginning of the hypertrophic zone. H. & E. original magnification $\times 55$.

cartilage (Fig. 2). It may be a matter of terminology, whether it is considered a specific tissue for this special cartilage, or just a perichondrium, producing cartilage through proliferation of its deeper cells (cf. Storey, 1972; Meikle, 1973). In any case, the tension from the muscle may be transmitted through the periosteum-perichondrium, which is most likely already under some tension of its own.

An intriguing feature seen in the condylar cartilage of young rats is the arrangement of collagen in an arch-like

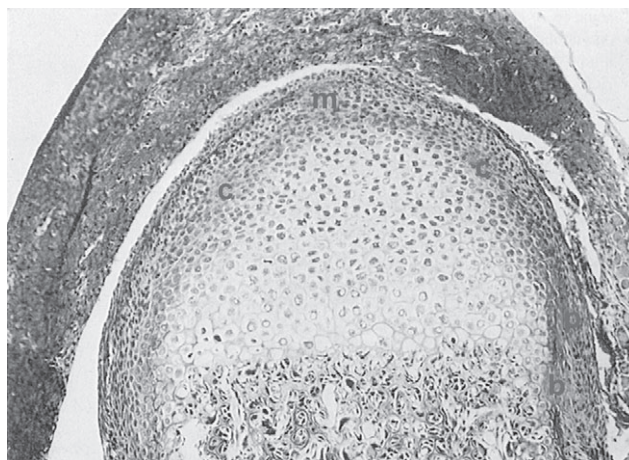

Figure 3 A frontal section of the condylar cartilage of a 20-day-old rat. There is an arch-like condensation of collagen (c) immediately below the mitotic zone (m), seemingly continuous with the periosteum (p) and the bony collar (b) of the lower condyle. Van Gieson, original magnification $\times 133$.

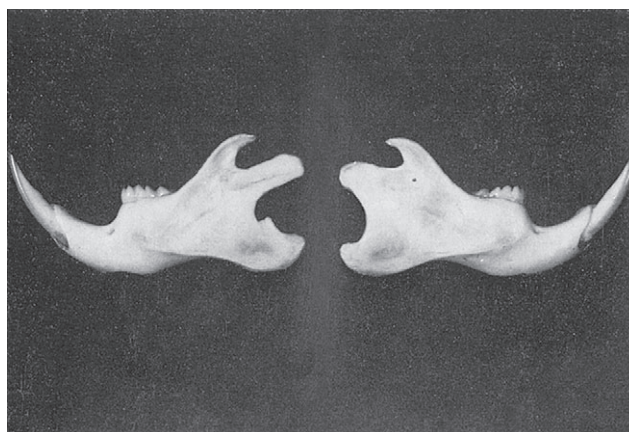


Figure 4 The halves of the mandible of a 51-day-old rat, whose condyle neck periosteum was circumcised at 21 days. The operated mandible (left) shows deviations from the normal growth pattern (right), localised in the ramus.

fashion just below the mitotic zone of cells (Fig. 3). This arch seems to be a 'branch' of the perichondrium, and it may thus be under the same tension as the perichondrium. Collagen has been linked with chondrogenesis, although views regarding its role vary (see Minor, 1973 for review).

Several different possibilities exist here. The collagen concentration may be just an expression of the productivity of the mesenchymal cells; perhaps we are dealing here with the same kind of divided labour as in other cartilage tissues (*vide supra*). On the other hand, the collagen band may be creating, between itself and the top perichondrium of the cartilage, a pressure area favourable for chondrogenesis (Wurmbach, 1967). It is also possible that collagen is associated in some more direct way with chondrogenesis (Trelstad *et al.*, 1973). As can be seen, the condylar cartilage offers an interesting model for investigations on interactions between connective tissue elements.

Preliminary observations on the effect of periostomy in the neck of the condyle of the rat have shown that the growth of the ramus is affected locally (Rönning and Koski, 1974; Fig. 4). The nature of the disturbance, including the possible effect on the mitotic rate of the cartilage, remains to be clarified in the course of ongoing studies. The statement that the condylar cartilage directs the growth of the mandible has been repeated in the past *ad infinitum*. While there may seem to be some grounds for it on a structural basis during embryonic and foetal development, it has never been proved. In post-natal life the statement is unacceptable on a structural basis in the majority of mammalian species (cf. Moss, 1968), certainly in man.

A look at the rat condyle will clarify the matter in some pertinent details (Fig. 2). The condylar cartilage proper, i.e., the differentiated cartilage cells, is enclosed in a tube of perichondral bone, very much like the perichondrial ring of long bones (Lacroix, 1952). The statement that the cartilage can exert orientated forces determining the direction of bone growth only when constrained by connective tissue or bone (Storey, 1972), could conceivably have an application here. However, when the direction of bone growth in the condylar process, i.e., the orientation of newly formed bone trabeculae, is observed, it can be noted that they can be significantly different from the main axis of the process and of the cartilage (Fig. 5). A 'directional growth of the condylar cartilage' (Bhaskar, 1953) seemingly does not direct the growth of its neighbouring ramus, let alone the mandible.

Another example illustrating the same point is offered by the rabbit mandible, where the condylar cartilage also has been stated to be responsible for the growth of the upper ramus (Bang and Enlow, 1967). This could be the relative truth only during the pre-natal and first few postnatal weeks. After the fifth week an increasing posterior part of the ramus is not growing under the cartilage, and by the ninth week this posterior part is already one half of the width of the ramus (Fig. 6). Furthermore, arrangement of the trabeculae of the ramus does not corroborate the view that the condylar cartilage directs the growth of the bony ramus (Fig. 7).

From these observations and discussions of the cellular and tissue aspects of ramal and condylar structure and function, we shall now move on to look at some macroscopic details of more direct relevance to orthodontics. In human foetuses the lower jaw, even after the formation of the condylar process, has the appearance of an essentially straight bone, the already prominent angular region notwithstanding (Fig. 8). The impression is easily gained that the condylar process with its cartilage has taken the lead in mandibular development. However, the body of the mandible has already been there for some time, and the condylar cartilage is a newcomer (cf. Duterloo and Jansen, 1970). The relationship between the condylar process and the mandibular canal, e.g., the inferior alveolar nerve which has been assumed to exert considerable influence on the mandibular growth (cf. Moss and Salentijn, 1970), is such

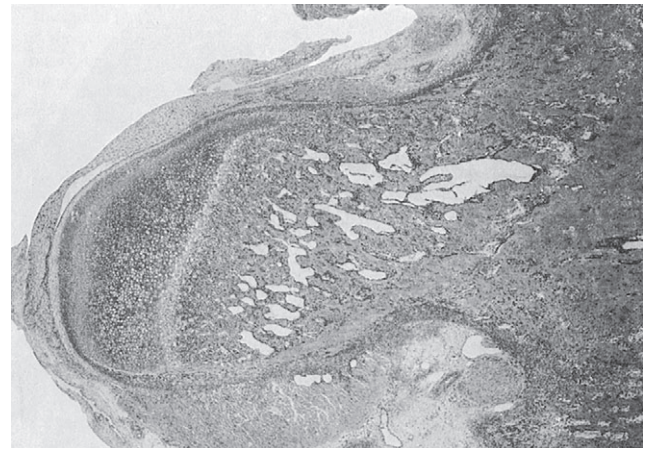


Figure 5 A sagittal section of the condylar process of a 15-day-old rat. Note that the direction of the trabeculae differs from the main axis of the process. H & E, original magnification $\times 34$.

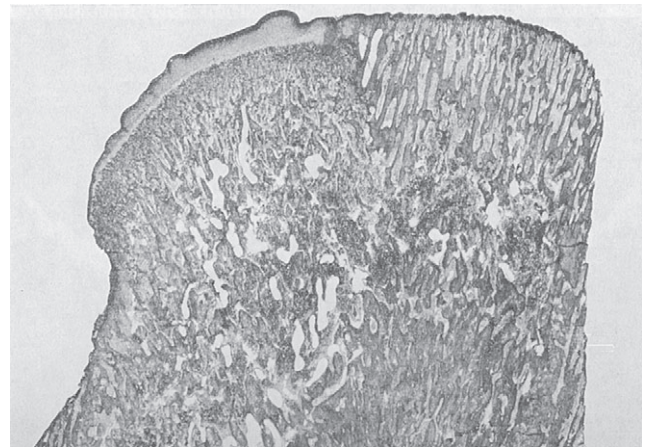


Figure 6 A sagittal section of the ramus of a 9-week-old rabbit, in which the cartilage covers only the anterior half of the ramus, and the posterior part has grown from the periosteum. H & E, original magnification $\times 18$.

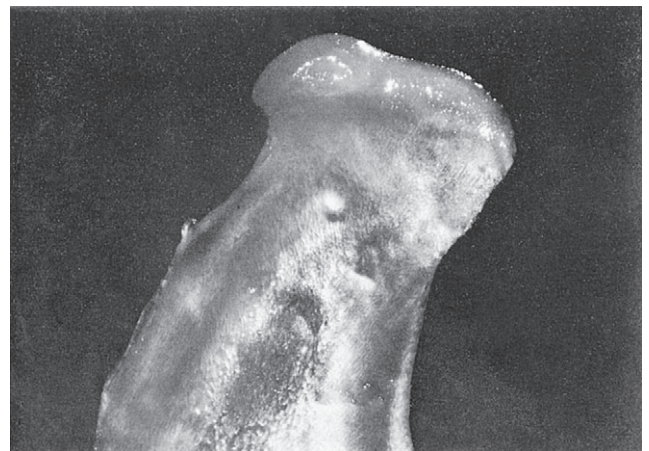

Figure 7 A macrophotograph of the ramus of a 5-week-old rabbit, illustrating the varying pattern of bone trabeculae in different parts of the ramus. The condylar cartilage is limited to the anterior 2/3 of the ramus top.

that the former seems to be the continuation of the latter. In the absence of any good evidence to the contrary, we have to conclude that even in the human foetus it is quite likely that the mandibular body is growing under directives from sources other than the condylar cartilage.

Cephalometric studies on child skulls (Koski, 1973) and on living children and young adults (Vinkka and Koski, 1975) have revealed some structural associations which do not seem to have received attention in the past (Fig. 9). There exists a parallelism between the infraorbital canals and the mandibular canals in all samples studied so far, including a sample of young *Macaca* monkeys (Vinkka *et al.*, 1975). In view of the significance attributed to the mandibular canal (Björk, 1969) and to the neural elements (Moss and Salentijn, 1970) this is interesting, although it naturally does not prove anything. Another detail of possible biological significance is the perpendicular relation of the condylar process to the cranial base. This seems to be in agreement with the principle that the axis of an articulating process of a bone is perpendicular to the base of the joint socket in the habitual or rest position. As will be seen later, this condyle-cranial base relationship may be a basic one, independent of possible mandibular malformations. (It should be realized, however, that it is subject to the usual biological variation). There seems to exist a parallelism between the condylar and pterygoid processes, very likely associated with the lateral pterygoid muscle. The variability of the condyle's relations to other parts of the mandible is very great.

The occlusion, so important to the orthodontist, has also been considered of central importance to the facial architecture from the biological point of view (cf. Zingeser, 1973). As regards the relation of the occlusal plane to the structural planes of the mandible, the least amount of variability is found between the occlusal plane and the mandibular canal and the base line of the jaw, and the greatest variability exists between the occlusal plane and the condylar direction.

If angular relationships in children and adults are compared, some seemingly stable structural configurations (on a cross-sectional basis!) emerge (Fig. 9).

One of these is the relationship between the occlusal plane and the anterior part of the mandibular canal, perhaps not so surprising because of their close spatial relationship. Another is a triad between the infraorbital canal, the posterior part of the mandibular canal, and the mandibular base line. The third one is found to include five planes of the cranial base, the palatal plane, and the planes depicting the ramus and the condyle. As many of these lines in the analytical method used can also be considered to represent the naso-pharyngeal cavity, the last mentioned configuration can be taken to imply an association between the ramus and the naso-pharynx. This association has been suggested before (e.g., Moss, 1968; Björk and Skieller, 1972), and our numerical findings (Vinkka and Koski, 1975) only indicate what could be deduced from the anatomy: the ramus and the condyle have numerous muscular and ligamental associations

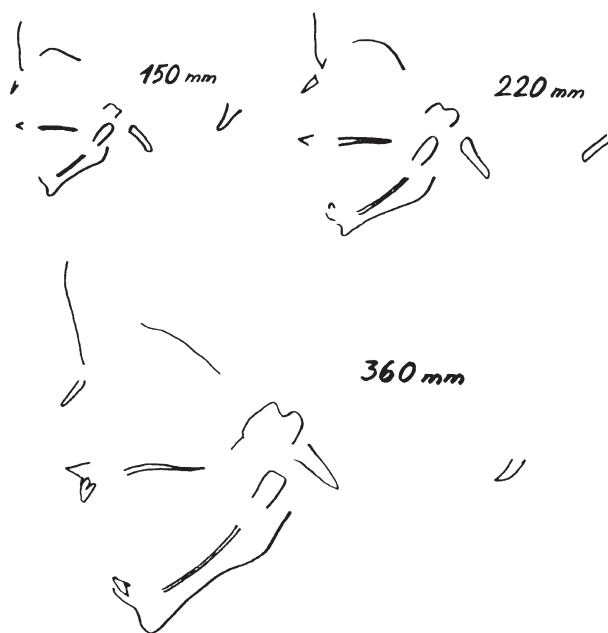


Figure 8 Tracings of X-ray cephalograms of three human foetuses of 150 mm, 220 mm, and 360 mm C-R length. Note the relatively straight appearance of the mandible, and the close relationship between the mandibular canal and the condylar process

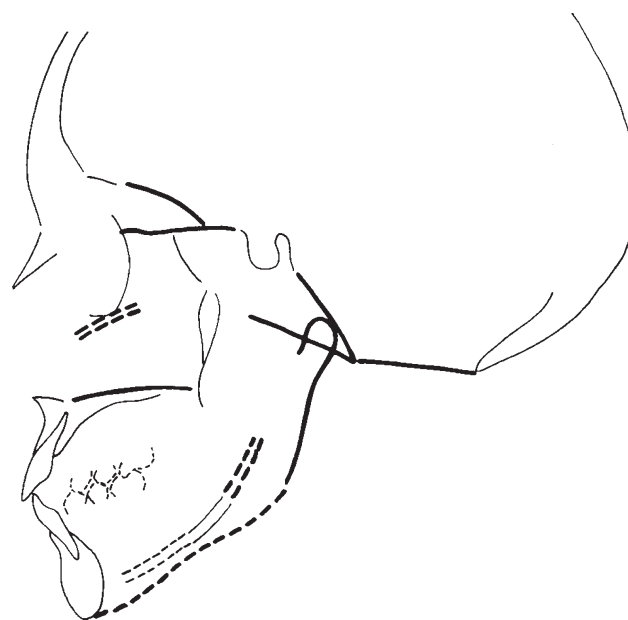


Figure 9 A tracing of an X-ray cephalogram showing the anatomical structures which have been studied using tangents or lines of best fit. Structures drawn with similar lines form cross-sectionally stable configurations.

with the pharynx-cranial base region. The fact that the tooth-bearing part of the mandible and the ramus-condyle part are not very strongly associated appears significant; from the phylogenetic viewpoint it is of course quite understandable. There are very good reasons for regarding the ramus-condyle part as an adjusting link between the masticatory part of the mandible and the skull (Koski, 1973). This also explains the

great variability in the condyle direction (Björk and Skieller, 1972), so difficult to reconcile with the idea that the condyle would be directing the mandibular growth.

It has been known for a long time that children with rheumatoid arthritis have characteristically malformed mandibles, although this 'is not to be considered pathognomonic, since such a change of mandibular contour may occur following any type of interference with the growth activity of both condyles' (Engel *et al.*, 1949). One change of mandibular contour apparently is the antegonial notching. This alone is most likely the result of increased activity of the suprahyoid muscles (cf. Tsukamoto *et al.*, 1968), when the movement of the condyle in an affected joint is limited. It is to be noticed, however that in many instances not only is the contour of the jaw abnormal, but also its rotational status, even the location of the temporomandibular joint itself (Fig. 10).

Similar findings can be made in cases of condylar hypoplasia (Björk, 1962) or of mandibular micrognathia associated with the Pierre Robin syndrome (e.g. Markovic, 1973), to mention only a few of the many situations with this type of mandibular development. The lack of proper condylar structure and activity undoubtedly plays a part, but how important a part? A recent observation (Koski and Lähdemäki, 1975) may throw some light on this issue. In children with pathologically enlarged adenoids the mandible is rotated in relation to the palate in the same way as in rheumatoid children, i.e., the dorsal surface of the ramus forms a right angle with the palatal plane (Fig. 11). This may or may not be associated with an antegonial notching. This finding, when considered together with the observations mentioned above, suggests very strongly that in all these cases there is a common factor in operation. The common factor is not difficult to identify. In all these different development disturbances, irrespective of condylar cartilage involvement, there is an encroachment on the pharyngeal space. In order to react – to adapt, to adjust – to this threat on life a series of emergency measures has to be undertaken, probably starting with the lowering of the tongue and soft palate, and ending with the rotation of the mandible. The presence of antegonial notching seems to depend primarily on the involvement of the joint, and not on defects of the condylar cartilage. The condyle is again found to be an adjusting part of the mandibular complex; it seems to maintain a perpendicular relationship to the cranial base in all these forms of facial maldevelopment. Hardly anything that has been discussed here is new. The myth of the all-important condylar cartilage obviously never had a chance of being scientifically verified, and belongs to history. The complexity of the mandibular bone has been known for a long time, and the relative independence of its functional parts has been proven. We now have a considerable amount of clinical data related to and proving the adaptability of the mandibular complex, and we have begun to learn what this adaptability means in terms of cellular and tissue function.

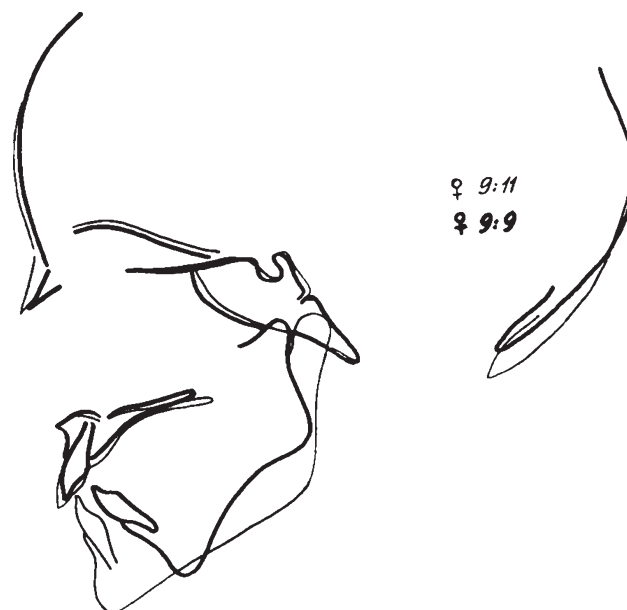

Figure 10 Tracings of X-ray cephalograms of a healthy girl, aged 9.11 years, and of a girl suffering from rheumatoid arthritis, aged 9.9 years, superimposed on the midcranial base outline. The characteristic deformation of the latter girl's mandible includes a marked antegonial notching, shortened ramus and dorsal rotation of the mandible. Note that the mandibular joint is abnormally located. The condyle is perpendicular to the cranial base.

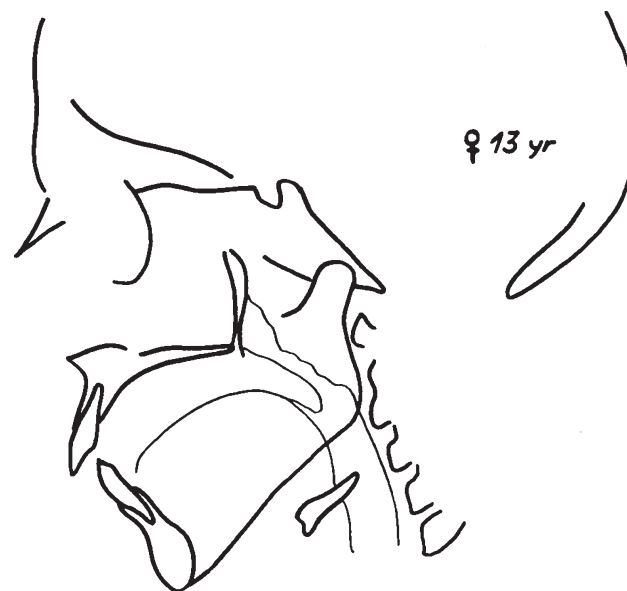


Figure 11 Tracing of the X-ray cephalogram of a 13-year-old girl with pathologically large adenoid tissue. The rotation of the mandible is similar to that of the rheumatoid girl in Figure 10: Note the perpendicular relation of the condyle to the cranial base.

At all levels of observation we find the same important phenomenon: a constant interaction between the elements. No one tissue or structural part can be considered the leader of post-natal growth and development; nor can the, often subtle, adaptive growth changes be consistently attributed primarily to genetic or environmental factors. Just as the

balance between the genetic and environmental factors is fluctuating during growth in the dimensions of space and time, so is the balance between the structural and functional factors in a given organ. Even if this or that tissue or organ part would seem to be the director of the process at a given time, the next moment may well change the picture.

This all means that we still have much to learn about our complex mandible to overcome our mandibular complex. The message is this: a thorough understanding of craniofacial biology cannot be achieved through one-sided reliance on cephalometry, comparative anatomy, histology or biochemistry; we have to pool the information obtainable through all the different channels of investigation. If orthodontics is to progress from its present art-like stage to a scientifically conducted discipline, we orthodontists should learn to appreciate critically the multitude of available information and apply it to our clinical endeavours.

Acknowledgements

The author's thanks are due to Mmes. Leena Oksa, Sirpa Roman and Leena Savonmäki for preparing the histological sections, and to Mr. Jarmo Koskinen for his skilful microphotography.

References

- Bang S, Enlow D H 1967 Postnatal growth of the rabbit mandible. *Archives of Oral Biology* 12: 993–998
- Bhaskar S N 1953 Growth pattern of the rat mandible from 13 days insemination age to 30 days after birth. *American Journal of Anatomy* 92: 1–53
- Björk A 1962 Facial growth in bilateral hypoplasia of the mandibular condyles. A radiographic, cephalometric study of a case, using metallic implants. In: Kraus B S, Riedel R A (eds) *Vistas in orthodontics*. Lea & Febiger, Philadelphia, p. 347
- Björk A 1969 Prediction of mandibular growth rotation. *American Journal of Orthodontics* 55: 585–599
- Björk A 1972 The role of genetic and local environmental factors in normal and abnormal morphogenesis. *Acta Morphologica Neerlandico-Scandinavica* 10: 49–58
- Björk A, Skieller V 1972 Facial development and tooth eruption. *American Journal of Orthodontics* 62: 339–383
- Bremers L M H 1973 *De Condylus Mandibulae In Vitro*. Proefschrift, Nijmegen
- Charlier J-P, Petrovic A, Hermann-Stutzmann J 1969 Effects of mandibular hyperpulsion on the prechondroblastic zone of young rat condyle. *American Journal of Orthodontics* 55: 71–74
- Crilly R G 1972 Longitudinal overgrowth of chicken radius. *Journal of Anatomy* 112: 11–18
- Duterloo H S 1967 *In vivo* implantation of the mandibular condyle of the rat. Proefschrift, Nijmegen
- Duterloo H S, Jansen H W B 1969 Chondrogenesis and osteogenesis in the mandibular condylar blastema. *Transactions of the European Orthodontic Society*, pp. 109–118
- Engel M B, Richmond J, Brodie A G 1949 Mandibular growth disturbance in rheumatoid arthritis of childhood. *American Journal of Diseases of Children* 78: 728–743
- Hert J 1964 Regulace rustu dlouhých kostí do delky. *Plzenský Lekarský Sborník Supplement* 12: 5
- Kincaid S A 1971 Histochemical evidence of a functional heterogeneity in adult canine articular chondrocytes. *Anatomical Record* 169: 456
- Koski K 1973 Variability of the craniofacial skeleton. An exercise in roentgen-cephalometry. *American Journal of Orthodontics* 64: 188–196
- Koski K 1975 Cartilage in the face. *Birth Defects Original Article Series* 11: 231–254
- Koski K, Lähdemäki P 1975 Adaptation of the mandible in children with adenoids. *American Journal of Orthodontics* 68: 660–665
- Koski K, Mäkinen L 1963 Growth potential of the transplanted components of the mandibular ramus of the rat. I. Suomen Hammaslaakariseuran Toimituksia 59: 296–308
- Koski K, Rönning O 1965 Growth potential of the transplanted components of the mandibular ramus of the rat. III. Suomen Hammaslaakariseuran Toimituksia 61: 292–297
- Lacroix P 1952 *The organization of the bones* Churchill, London
- Markovic M 1972 Growth changes in cases of mandibular micrognathia. *Transactions of the European Orthodontic Society*, pp. 133–145.
- Meikle M C 1973 The role of the condyle in the postnatal growth of the mandible. *American Journal of Orthodontics* 64: 50–62
- Minor R R 1973: Somite chondrogenesis. *Journal of Cell Biology* 56: 27–50
- Moss M L 1968 Functional cranial analysis of mammalian mandibular ramal morphology. *Acta Anatomica* 71: 423–447
- Moss M L, Salentijn L 1970 The logarithmic growth of the human mandible. *Acta Anatomica* 77: 341–360
- Petrovic A, Stutzmann J 1972 Le muscle ptérygoïdien externe et la croissance du condyle mandibulaire. *Recherches expérimentales chez le jeune rat. L'Orthodontie française* 43: 271–285
- Petrovic A, Oudet C, Gasson N 1973 Effects de appareils de propulsion et de rétropulsion mandibulaire sur le nombre des sarcomeres en série du muscle ptérygoïdien externe et sur la croissance du cartilage condylien du jeune rat. *L'Orthodontie française* 44: 191–212
- Rönning O 1966 Observation on the intracerebral transplantation of the mandibular condyle. *Acta Odontologica Scandinavica* 24: 443–457
- Rönning O, Koski K 1969 The effect of the articular disc on the growth of condylar cartilage transplants. *Transactions of the European Orthodontic Society*, pp. 99–108
- Rönning O, Koski K 1974 The effect of periostomy on the growth of the condylar process in the rat. *Proceedings of the Finnish Dental Society* 70: 28–29
- Silbermann M, Frommer J 1973 Heterogeneity among chondrocytes of the mandibular condyle in foetal and postnatal mice. *Archives of Oral Biology* 18: 1549–1554
- Smith P H 1972 Autoradiographic evidence for the concurrent synthesis of collagen and chondroitin sulfates by chick sternal chondrocytes. *Connective Tissue Research* 1: 181
- Storey E 1972 Growth and remodelling of bone and bones. *American Journal of Orthodontics* 62: 142–165
- Trelstad R L, Kang A H, Cohen A M, Hay E D 1973 Collagen synthesis *in vitro* by embryonic spinal cord epithelium. *Science* 179: 295–297
- Tsukamoto S, Umeda T, Tmari Y, Kawakatsu K 1968 Electromyographic activities of jaw muscles in ankylosis of the temporomandibular joint. *Oral Surgery, Oral Medicine, and Oral Pathology* 25: 117–130
- Vinkka H, Koski K 1975 Variability of the craniofacial skeleton. II. Comparison between two age groups. *American Journal of Orthodontics* 67: 34–43
- Vinkka H, Koski K, McNamara J 1975 Variability of the cranio-facial skeleton III. Radiographic cephalometry of juvenile *Macaca mulatta*. *American Journal of Orthodontics* 68: 1–7
- Wurmbach H 1967 Wirksame Kräfte beim Wachstum, der Formgestaltung und der Gewebsdifferenzierung. *Oral Surgery, Oral Medicine, and Oral Pathology* 66: 520–602
- Youdelis R A 1966 Ossification of the human temporomandibular joint. *Journal of Dental Research* 45: 192–198
- Zingeser M R 1973 Occlusofacial morphological integration. IVth International Congress Primat vol. 3: 241